

AUGIS Travelling Fellowships

Reports on the AUGIS Travelling Fellowships

Visit to the Cancer Hospitals in Tokyo, Japan: Cancer Institute Hospital (CIH) and National Cancer Centre (NCC)

Mr P S Jambulingam, Luton & Dunstable Hospital

I had the pleasure of visiting the Cancer Hospitals in Tokyo during the cherry blossom season in April. The main purpose of this visit was to improve on my minimally invasive techniques in delivering Oesophagogastric resectional services (MIO) for the South Bedfordshire and Hertfordshire UGI Cancer Network.



The Division of Gastric cancer surgery at CIH is lead by Dr Takeshi Sano who was instrumental in organising this visit for me. This unit has 4 other surgeons: Dr Yamaguci (Head of Gastroenterology), Dr Ohyama, Dr Naoko Hiki and Dr Fukanaga (the last 2 are laparoscopic Protagonists). At the NCC the oesophageal division is headed by Dr Tachimori and the Gastric Division comprised of Dr Hitoshi Katai, Dr Takeo Fukugawa and Dr Makoto Saka.

Both units perform 10 to 12 gastrectomies a week and 50% of these were for early gastric cancers. During my 2 weeks here, I attended 19 gastrectomies (6 were laparoscopic assisted- LAG) and 3 oesophagectomies (1 thoracoscopic). D2 gastrectomy was performed for tumours T2 and beyond. This is performed with an aura of confidence, anatomical familiarity, surgical finesse bred through dedication, consistent with high volume exposure and systematic practice & training. The mortality is <1% and morbidity is 22% (Pancreatic fistula, abscess, anastomotic leak and pneumonia) Laparoscopic resections are undertaken only for T1 or early T2 tumours in the form of Laparoscopic Assisted Distal Gastrectomy (LADG) or Pylorus Preserving Gastrectomy (LAPPG). Pylorus preserving Gastrectomy (PPG) are performed for lesions <1 cm, well differentiated, 4cm or more from the pylorus by taking care in the dissection of the right gastro-epiploic artery, preserving the

infra-pyloric branch of this vessel to preserve the pylorus. The tumours are endoscopically clipped pre-operative to allow identification of tumours prior to division of the stomach. Dr Tachimori and his team displayed the techniques in MIO and radical neck dissection, took special interest in showing me the anatomy and the various steps involved. I picked up clues in positioning the ports, use of Harmonics & Ligasure and techniques in lymph node dissections and anastomosis.

At the NCC, Dr Katada, lead endoscopist, pioneered endoscopic sub mucosal dissection (ESD) and developed the special IT knife. I had the opportunity to observe one ESD which was done with great precision removing a large area of mucosa and sub mucosa dissected off down to the muscle. More than 200 ESDs have been performed with a perforation rate of 3%, all managed successfully with endoscopic clips with no mortality.

The contrasting features that stood out were the immaculately clean hospital, punctual ward rounds, meetings & Theatre starts, the extremely proficient scrub nurses and the abundance of juniors to assist in theatres. Patients with BMI rarely >27, absence of nurses on the daily ward rounds and the productive Surgeon led MDT (absence of Radiologists, Oncologists and Pathologists) were the other striking differences.



I thoroughly enjoyed my stay and hope this experience will go a long way in improving my delivery of MIO in the future. I would like to thank Dr T Sano and his colleagues for their generous hospitality and spending their invaluable time in making my stay enjoyable and educational. I would also like to thank AUGIS committee for granting me the AUGIS travelling fellowship.

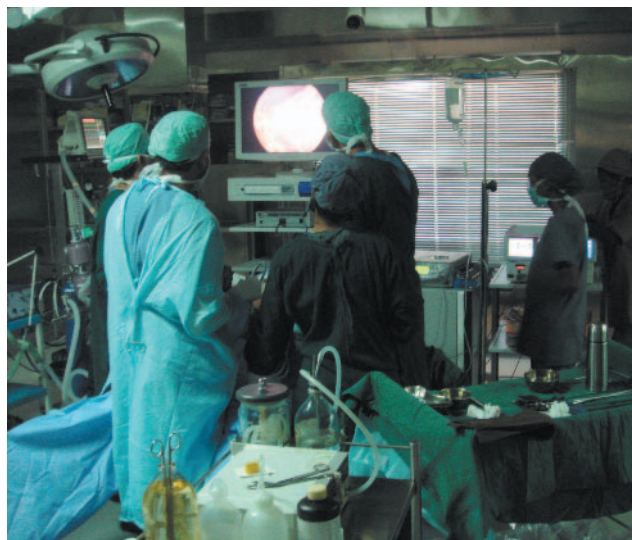A Trip of Contrasting Experiences Mr Stewart Duncan, Chesterfield Royal Hospital

Leaving seasonal UK temperatures of 7-8 °C in late March, I arrived in Coimbatore with daytime temperatures in excess of 35 °C. I was very grateful then, to be in the air conditioned theatre suite of GEM Hospital early the following morning. GEM Hospital (figure 1) was founded in 1991 by Dr C Palanivelu and is a 200-bedded private hospital managing a range of surgical and medical gastro-intestinal conditions.



Dr Palanivelu, the Chief, heads 3 surgical teams, with each team individually led by a senior surgeon (which would probably compare most accurately to the old senior registrar grade in the UK). The teams “rotate” through clinic, operating and ward work days so that a patient with for example, symptomatic gallstones, seen in the clinic is frequently operated on the following day by the same team and discharged from the ward the day after that. The referral pattern of patients to the clinic is in many ways similar to that in the UK. Patients may be referred by family physicians or they may receive referrals from other clinics but crucially and in a very different manner to the UK system, patients may also present themselves to the hospital, with the reputation of the Institution largely responsible for these self-referrals. With the influence of cultural differences, the fee-paying nature of the patients and the importance of reputation, it is not unusual for a patient presenting with suspicious upper or lower gastro-intestinal symptoms to undergo diagnostic tests, cross-sectional imaging and any medical consultations required before definitive operative intervention all within the space of 4-5 days.

Operations are carried out 6 days a week, with the case mix and the operating surgeon decided by the Chief depending on ability, experience and training needs. The vast majority of cases are approached laparoscopically, in both elective and emergency situations. There are 6 dedicated theatres (figure 2); all with high definition imaging systems and the harmonic scalpel is used in all cases requiring tissue dissection. They perform approximately 50 oesophageal resections a year and have adopted a minimally invasive approach. The procedure begins with thoracoscopic mobilisation of the oesophagus with the patient in the prone position. The patient is then turned supine, allowing laparoscopic gastric mobilisation, lymphadenectomy, pyloroplasty and formation of the gastric conduit, with a cervical anastomosis. Dr Palanivelu has also performed laparoscopic transhiatal resections.



The range of surgical procedures performed during my visit was extensive considering the usual practices of a single surgeon in the UK. Including upper gastro-intestinal resections for malignancy, other procedures included pancreatic resections, extended cholecystectomy, bariatric procedures (sleeve gastrectomy and duodenal switch), a range of colorectal operations and even some gynaecological procedures.

In stark contrast to the working practices at GEM hospital in Coimbatore, I spent four weeks observing the work of Dr J Luketich, at the University of Pittsburgh Medical

AUGIS Travelling Fellowships



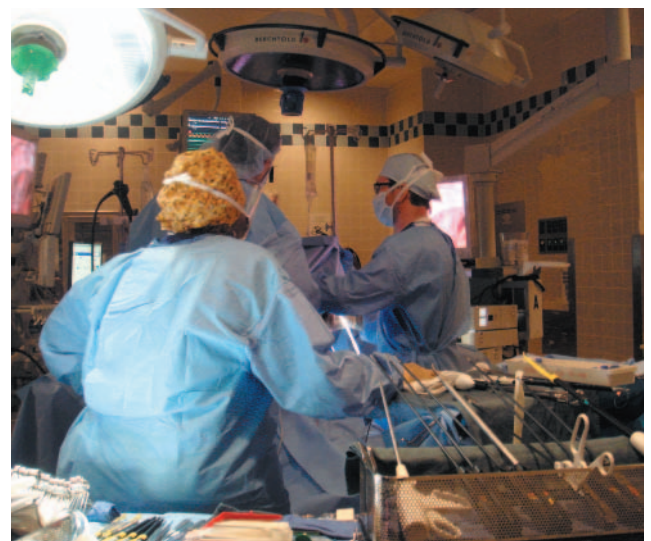Centre (UPMC). Dr Luketich is the Director of the Heart, Lung and Esophageal Surgery Institute (HLESI) and Chief of Thoracic Surgery at UPMC. Although UPMC itself is comprised of a number of sites in and around Pittsburgh, the majority of the oesophago-gastric surgery is carried out at Presbyterian hospital (figure 3) close to the University and the Medical School.

UPMC has an excellent reputation for training with stiff competition for the residency program. There are also a number of fellows who come from all over the world to work with Dr Luketich, usually for a period of 1 year. Dr Luketich was routinely present in the operating room on Mondays, Wednesdays and Fridays and this is when all major oesophago-gastric cases are carried out. There were usually three rooms working concurrently, with Dr Luketich moving from room to room carrying out the more complicated steps of individual procedures. Up until 2005, he utilised a 3-stage approach to resection, but now prefers a two-stage procedure with a stapled, intra-thoracic anastomosis. The procedure begins with laparoscopic gastric mobilisation and formation of the conduit. Thoracoscopic mobilisation of the oesophagus, lymph node dissection, resection and restoration of continuity is carried out with the patient on their left side. The procedure is performed without epidural analgesia, but local anaesthetic is infiltrated into the intercostal spaces under direct vision prior to the end of the procedure. The majority of patients are extubated in the operating room and spend a single night in the surgical ICU. As

long as there are no post-operative complications, the aim is to discharge patients home on the 5th or 6th post-operative day. Using this approach Dr Luketich and his team have reduced the anastomotic leak rate requiring surgical intervention to 2%.

The management of simple and complex situations attributable to gastro-oesophageal reflux disease also forms a significant component of the work undertaken in the unit. The initial procedure of choice is a Nissen-type fundoplication, with the liberal use of the Collis gastroplasty for the shortened oesophagus. An aggressive surgical policy is adopted for those with ongoing or recurrent symptoms and re-do fundoplication, oesophago-jejunostomy or even oesophago-gastrectomy are all utilised depending on the situation. I was able to observe all of these situations during my visit and was fortunate to attend a course designed specifically to address and discuss the role of surgery in the management of complex benign oesophageal disorders.

The increasing use of minimally invasive techniques in the surgical management of oesophago-gastric malignancy in the UK has led to UK trainees and Consultants seeking practical and observational experience in various parts of the world. A significant number of those have been supported financially by the AUGIS fellowship awards. I am very grateful to count myself in this group and I am indebted to AUGIS and Drs Palanivelu and Luketich for enabling me to complete this trip.



Department of Gastrointestinal Surgery, University Hospital of Heidelberg

Chief of Division: Professor Buchler
Mr Giuseppe Garcea, Leicester Royal Infirmary

The University Hospital of Heidelberg is one of the largest and most renowned medical centers in the Federal Republic of Germany. It is closely linked to Heidelberg University Medical School (Heidelberg University Faculty of Medicine) which was founded in 1388 and is thus the oldest within the Federal Republic of Germany. The Department of Surgery has a major pancreatic unit, which undertakes over 400 pancreatic resections per year.



Department of Surgery in Heidelberg

The volume of work undertaken at Heidelberg is extraordinary and far in excess of what would be typically be expected for a unit of its size in the relatively small (although breath-taking) city of Heidelberg. The department practices an extremely aggressive approach in determining resectability of pancreatic cancers and their ethos and approach to pancreas cancers was extremely interesting to observe. Research also forms a major component in the unit and a regular procession of research fellows would attend each pancreatic resection to sample blood or bone marrow. I was made to feel extremely welcome I would hope to visit again in the future.

Views from the Castle in Heidelberg and the Stunning Scenery



Heidelberg Castle




AUGIS Travelling Fellowships

Department of General, Minimally Invasive and Robotic Surgery, University of Illinois

Chief of Division:

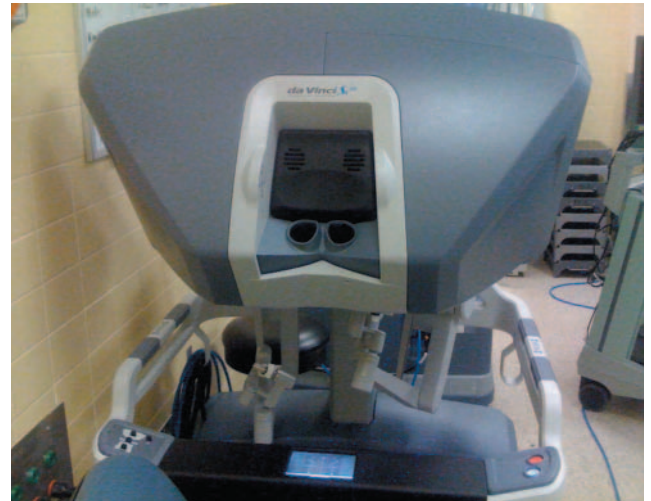Professor Pier Cristoforo Giulianotti

The first robotic procedure was undertaken in 1985 by the PUMA 560, which placed a brain biopsy needle under CT guidance. Since that time robotic systems have evolved into the present “state of the art” da Vinci Surgical System. This consists of a surgeon’s console, patient side robotic cart (with 4 arms manipulated by the surgeon) and a high-definition three dimensional vision system. The surgeon’s hand movements are scaled and filtered to eliminate hand tremor then translated into micro-movements of the proprietary instruments. The camera used in the system provides a true stereoscopic picture transmitted to a surgeon’s console.



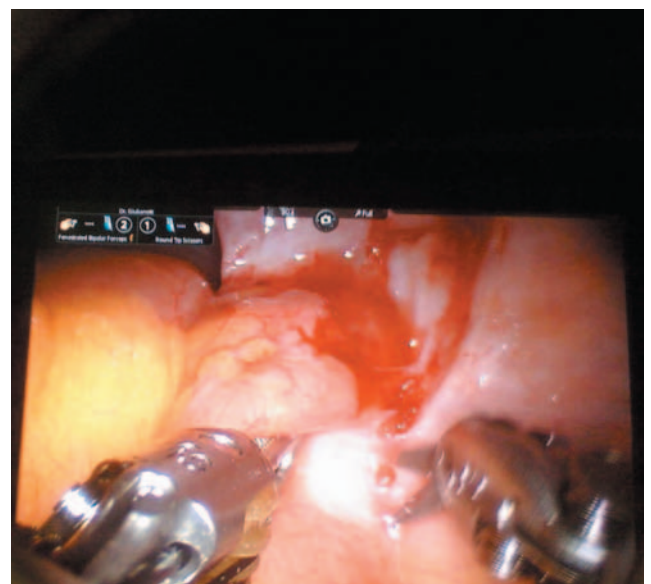Robotic Simulator in Chicago

Dr. Pier Cristoforo Giulianotti is a Professor of Surgery and Chief of The Division of General, Minimally Invasive, and Robotic Surgery at The University of Illinois at Chicago. In the last eight years he has developed the largest program worldwide for robotic surgery. He has performed over 2100 minimally invasive surgeries of which more than 914 have been robotic procedures. Dr. Giulianotti has been the first in the world to perform procedures such as formal hepatic resection, lung resection and pancreaticoduodenectomy using the robotic system. Dr. Giulianotti is currently



Actual Surgical Robot

considered the foremost robotic surgeon worldwide. The opportunity to observe this technology and witness its capabilities was extremely exciting. Outside of the field of Urology, the da Vinci robotic system has yet to make a significant impact in the United Kingdom, but as Dr Giulianotti and his colleagues have demonstrated, it has very pertinent applications in liver and pancreatic surgery.



Intraoperative view of Robot in use

Princess Alexandra Hospital, Brisbane, Australia and the Cancer Institute Hospital JFCR, Tokyo, Japan

Rachel Melhado, Queen Elizabeth Hospital

Princess Alexandra Hospital, Brisbane

I arrived in Brisbane in eager anticipation of the prospect of spending two weeks in one of the pre-eminent centres for thoracoscopic oesophageal surgery and was not disappointed. I received a warm welcome from Professors Mark Smithers and David Gotley, Drs Ian Martin and Andrew Barbour and their UK surgical fellow Andrew Macdonald and their teams which span the public and private hospitals. The unit has performed over 500 thoracoscopically assisted three-stage oesophagectomies, having pioneered the technique in the mid 1990's following Cuschieri's description. The surgery was technically excellent and effortless with the thoracic component including radical lymphadenectomy taking just over an hour with the entire procedure completed on an extended half-day list. Cases are selected for the thoracoscopic approach with approximately 1/3 cases deemed unsuitable due to large tumour bulk at the gastro-oesophageal junction with a substantial gastric component, these undergo an Ivor Lewis procedure.



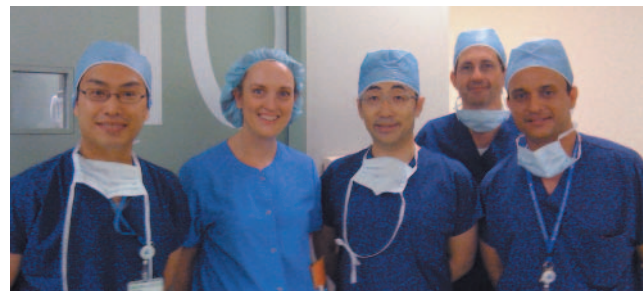Drs Martin, Gotley, Melhado, Smithers, Barbour and Macdonald at the Princess Alexandra Hospital, Brisbane

I also benefited greatly from the units extensive experience of anti-reflux surgery, picking up various technical tips. To date they have performed over 2000, encompassing a transition from Nissen's to partial funduplications (both Toupé and anterior), as a result of their participation in randomised controlled trials.

The Cancer Institute of the JFRC, Tokyo

The Cancer Institute undertakes over 600 resections and 300 endoscopic submucosal dissections (ESD) for gastric cancer annually and during my two week visit performed an astonishing 28 gastric cancer resections. Dr Takeshi Sano, a brilliant technical surgeon hosted my visit, demonstrating and explaining the rationale and latest Japanese evidence relating to radical D2 lymphadenectomy including portal triad dissection, bursectomy and splenectomy. Approximately 50% of cases are node negative early gastric cancer, these are

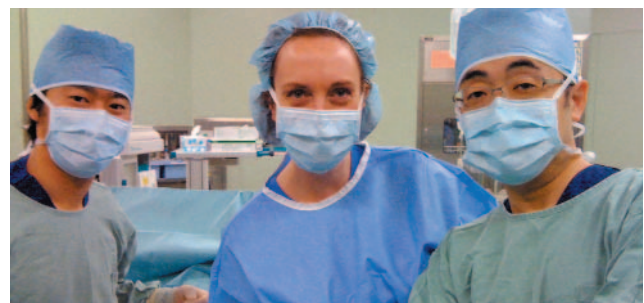resected laparoscopically if they do not meet the criteria for ESD. Laparoscopic gastrectomy has been honed to a fine art, generally taking less than three hours and was demonstrated beautifully by Dr Naoki Hiki and his team. In addition to standard distal and total gastrectomy, laparoscopic pylorus preserving gastrectomy and near total gastrectomy for tumours situated 3cm from the gastro-oesophageal junction, leaving a very small gastric remnant are practiced. Each procedure is performed in discrete steps which aids the learning curve. Coordination between gastroenterologists and surgeons ensures resection margin adequacy by pre-operative tumour marking with endoscopically placed clips. Specimens are opened in theatre to ensure adequate margins; lymph nodes stations are dissected by the surgical residents and sent separately for histopathology.



Dr Hiki with international visitors to The Cancer Institute

I also took the opportunity to observe oesophagectomy with three field lymphadenectomy performed by Dr Mine and Dr Yamada whose demonstration of thoracic anatomy, especially the recurrent laryngeal nerves was impressive. It was a great opportunity to compare and contrast the management of squamous cell carcinoma with that of oesophageal adenocarcinoma.

This experience has had a huge impact on me and provided me with ideas to incorporate into surgical practice as I move into the next stage of my surgical career. I am grateful to Augis for the award of a travelling fellowship that has had enabled this pivotal time in my career.



With Dr Hiki having completed a laparoscopic pylorus preserving gastrectomy